25 questions **w/ answers** from AMBOSS Qbank – Surgery Shelf (paid subscription for Step 2)

1. A 29-year-old man who lives in Utah comes to the emergency department 90 minutes after he received a snake bite on his right leg. He was cleaning out a shed in his backyard when he saw a snake between two beams of wood. When he tried to kill the snake with a shovel, it bit him in the lower leg. He says, “I don't really remember what it looked like other than that it was brown; I had a few beers before I started clearing out the shed, so it's all a bit fuzzy.” The bite site is painful. He is nauseous and says that he feels like he is about to vomit. He has no significant past medical history and takes no medications. His temperature is 37.3°C (99.1°F), pulse is 105/min, respirations are 26/min, and blood pressure is 96/52 mm Hg. Cardiopulmonary examination shows no other abnormalities. Physical examination shows two erythematous puncture wounds with serous drainage just above the right ankle. There is ecchymosis and swelling across the dorsum of the right foot and the lower leg up to the mid-shin. Active and passive range of motion of the right knee and ankle is limited by pain. Neurologic examination of the extremities shows no abnormalities. Which of the following is the most appropriate next step in management?

Tip: The majority of snake bites in the US are by Crotalinae species, which are typically earth-toned. Treatment of snake envenomation is determined by the severity of clinical manifestations. This patient presents with systemic features, including nausea, tachycardia, tachypnea, and mild hypotension, which are consistent with envenomation of moderate severity.

Administration of antivenom
69%
Administration of antivenom is the most appropriate next step in management of a patient with moderate to severe envenomation by a crotaline snake. The clinical manifestations of envenomation are generally classified into three categories: local tissue effects (e.g., swelling and pain), systemic effects (e.g., tachycardia, hypotension, vomiting), and coagulopathic effects (e.g., hemorrhage, abnormal coagulation parameters). Severe cases can result in compartment syndrome, respiratory failure, life-threatening hypotension, and significant bleeding. Antivenom therapy can slow or halt the progression of toxicity and is most effective when administered within 6 hours of the snakebite. Crotalidae polyvalent immune fab and crotalidae immune f(ab')2 are the antivenoms available in the United States. Patients who have received antivenom should be monitored for hypersensitivity (e.g., serum sickness, anaphylaxis). Additional management recommendations include pain control, local wound care, tetanus immunization, and close observation, including regular monitoring of vital signs, tissue swelling, and coagulation studies.

Application of a tourniquet around the right lower leg
6%
Tourniquets and constrictive dressings are generally not recommended after a snakebite. Though constriction may theoretically delay venom spread through lymphatic channels, there is no evidence that this intervention provides any clinical benefit. Moreover, tourniquets can worsen local ischemia and tissue damage. Oral suction and cutting of the wound should also be avoided in the management of snakebite wounds, as their efficacy has not been proven.

Compartment pressure measurement in the right lower leg
13%
Compartment syndrome is a rare complication of snakebites and typically manifests with pulselessness, paresthesia, pallor, and pain on passive stretch. Although this patient presents

with limited range of motion of the right knee and ankle due to pain, he has no other symptoms of compartment syndrome. Direct measurement is only indicated in patients with clinical features of increased compartment pressure. Therefore, another step in management is more appropriate at this time.

Hospitalization and close observation of coagulation studies over 24 hours
11%
Patients with dry bites (in which no envenomation occurs) or mild envenomation from crotaline snakes can experience localized pain and swelling and should be hospitalized for pain control, local wound care, and close observation, including regular monitoring of vital signs, tissue swelling, and coagulation studies. This patient, however, has systemic features, including nausea, tachycardia, tachypnea, and mild hypotension, which are consistent with envenomation of moderate severity. Moderate to severe envenomation requires active treatment rather than observation alone.

Administration of neostigmine and endotracheal intubation
1%
Neurotoxic venom can cause neuromuscular blockade and diaphragmatic paralysis, which require neostigmine administration and intubation. Though some North American snakes have neurotoxic venom (e.g., coral snakes and some rattlesnakes), this patient does not have any neurologic symptoms, which makes acute neurotoxicity less likely. If he were to develop muscle weakness, upper airway obstruction, or significantly altered mental status, neostigmine administration and intubation might be indicated. However, they are not the most appropriate next steps in management at this time.

Administration of unfractionated heparin
1%
Hematologic toxicity is a common effect of crotaline envenomation and typically results in abnormalities in coagulation parameters (e.g., prolonged prothrombin time, hypofibrinogenemia, thrombocytopenia), in part due to the activity of thrombin-like glycoproteins from the venom. These glycoproteins are not inhibited by the action of heparin, which plays no role in the management of crotaline envenomation and may increase the risk of bleeding.

2. A 22-year-old man comes to the emergency department for pain and swelling of his left knee one day after injuring it while playing soccer. While sprinting on the field, he slipped as he attempted to kick the ball and landed on the anterior aspect of his knee. He underwent an appendectomy at the age of 16 years. His vital signs are within normal limits. Examination shows a swollen and tender left knee; range of motion is limited by pain. The tibial tuberosity shows tenderness to palpation. The left tibia is displaced posteriorly when force is applied to the proximal tibia after flexing the knee. The remainder of the examination shows no abnormalities. An x-ray of the left knee joint shows an avulsion fracture of the tibial condyle. Which of the following is the most likely diagnosis?

Anterior cruciate ligament injury
14%

Lateral meniscus injury
0%

Posterior cruciate ligament injury

84%
Posterior cruciate ligament (PCL) injuries are either noncontact injuries involving hyperflexion of the knee on a plantarflexed foot (most commonly seen in athletes) or injuries caused by a posterior blow to the flexed knee (e.g., dashboard injury, athletic contact injury). A positive posterior drawer sign is highly suggestive of PCL injury, and the diagnosis can be confirmed by MRI. Avulsion fractures are common in PCL injury. Isolated PCL injury can be treated conservatively; multiligament injuries and/or chronic symptoms typically warrant surgery.

Patients with PCL injury sometimes appear to have a positive anterior drawer sign because the affected knee seems to have significantly more anterior movement compared to the unaffected knee (due to starting from a posteriorly displaced position).

Lateral collateral ligament injury
1%

Medial meniscus injury
0%

Medial collateral ligament injury
1%

3. A 7-year-old boy is brought to the physician because of a 3-day history of fever, headache, earache, and sore throat that is worse when swallowing. He has not had a runny nose or cough. He had a similar problem 1 year ago for which he was prescribed amoxicillin, but after developing a skin rash, facial swelling, and dyspnea he was switched to a different medication. His immunizations are up-to-date. He is at the 75th percentile for height and the 50th percentile for weight. His temperature is 38.9°C (102°F), pulse is 136/min, and respirations are 28/min. Examination of the oral cavity reveals a bright red tongue with prominent papillae, a red uvula, and an enlarged right tonsil covered by a whitish membrane. The deep cervical lymph nodes are enlarged and tender. Which of the following is the most appropriate next step in treatment?

Tip: A modified Centor score of 5 (age 3–14 years, swollen tonsil with an exudate, tender anterior cervical lymph nodes, temperature > 100.4°F or > 38°C, and absence of cough) indicates a high likelihood of acute bacterial tonsillitis, which is most commonly caused by Streptococcus pyogenes. This patient also appears to have had a severe allergic reaction to amoxicillin in the past as suggested by the facial swelling (angioedema) and dyspnea.

Penicillin V
10%
S. pyogenes is the most common cause of bacterial tonsillitis and is uniformly sensitive to penicillin, making penicillin V the first-line treatment. However, given this patient's history of allergic reaction to amoxicillin (e.g., skin rash and facial swelling), penicillin antibiotics are contraindicated.

Total tonsillectomy
7%
Total tonsillectomy poses a risk of postoperative bleeding. Indications for tonsillectomy include chronic tonsillitis, suspected tonsillar neoplasm, obstructive sleep apnea (due to extreme

hypertrophy of the tonsils), and multiple recent recurrences of acute tonsillitis. Total tonsillectomy is not a suitable initial treatment for a child with an uncomplicated disease course, no signs of peritonsillar abscess, and only two episodes of acute tonsillitis within a year.

Subtotal tonsillectomy
3%
Subtotal tonsillectomy poses a risk of postoperative bleeding. Indications for tonsillectomy include chronic tonsillitis, suspected tonsillar neoplasm, obstructive sleep apnea (due to extreme hypertrophy of the tonsils), and multiple recent recurrences of acute tonsillitis. Subtotal tonsillectomy is not a suitable initial treatment for a child with an uncomplicated disease course, no signs of peritonsillar abscess, and only two episodes of acute tonsillitis within a year.

Fluconazole
2%
The whitish membrane seen covering this patient's tonsil could be a finding of oral Candida infection (i.e., thrush), which is typically treated with fluconazole. However, in a healthy child with a fever and acute tonsillitis, this whitish membrane is more likely due to tonsillar exudates. Fungal infections are more common in immunosuppressed or systemically ill individuals.

Clarithromycin
56%
This patient presents with tonsillitis that is likely due to a bacterial infection, which is normally treated with penicillin V. However, penicillins are contraindicated in this patient because of his past severe IgE-mediated allergic reaction to another penicillin antibiotic. Macrolides, such as clarithromycin or azithromycin, are the antibiotic of choice to treat acute bacterial tonsillitis in patients with a history of a severe penicillin allergy. If local macrolide resistance rates are high, clindamycin should be considered. Before initiating antibiotic therapy for suspected acute group A streptococcal tonsillopharyngitis, a rapid strep test should be obtained to confirm GAS infection.

Cefixime
22%
Cefixime is a 3rd generation cephalosporin and up to 10% of patients with a penicillin allergy are also allergic to cephalosporins. Cephalosporins may be considered in patients with previous nonsevere reactions to penicillin (i.e., reactions without angioedema or anaphylaxis) but should not be used in patients who have had a previous severe reaction to penicillin. Moreover, when cephalosporins are used for the treatment of tonsillitis or pharyngitis, 1st generation cephalosporins (e.g., cephalexin, cefadroxil) are preferred; 3rd generation cephalosporins are least active among all cephalosporins against gram-positive bacteria such as S. pyogenes.

4. A 66-year-old man comes to the office because of a 2-day history of intermittent red urine. He has not had flank pain, fever, dysuria, or increased urinary frequency. He has no history of recent trauma. Medical history is remarkable for hypertension and atrial fibrillation. His medications include lisinopril and warfarin. He does not smoke or drink alcohol. Temperature is 36.8°C (98.2°F), pulse is 72/min, respirations are 18/min, and blood pressure is 137/64 mm Hg. Abdominal examination shows no abnormalities. Digital rectal examination shows a smooth, normal-sized prostate without any irregularities. Laboratory studies show:

Hemoglobin 14.0 g/dL
Prothrombin time 48 sec (INR = 4)

Serum
Creatinine 1 mg/dL
Urine
Blood 3+
Protein negative
RBC too numerous to count
WBC 2/hpf
Casts none
Nitrites negative
Leukocyte esterase negative

In addition to adjusting the patient's warfarin dosage, which of the following is the most appropriate next step in management?
Tip: Painless gross hematuria is the most common manifestation of bladder cancer, so this patient requires a thorough diagnostic evaluation irrespective of his supratherapeutic INR.

Repeat urinalysis in one week
17%

Urine culture
1%

Ultrasound of the kidneys and bladder
19%

Retrograde pyelography
2%

Cystoscopy
61%
Cystoscopy is indicated in any patient with gross hematuria that is not explained by UTI (i.e., negative nitrites and leukocyte esterase on urine dipstick) or glomerular disease (i.e., no proteinuria). This procedure enables direct visualization of the urethral and bladder mucosa with possible biopsy collection and can reliably detect malignancy or other sources of bleeding. Cystoscopy should be combined with CT urography for evaluation of the entire urinary tract.

Cystoscopy is also indicated in men ≥ 40 years of age and women ≥ 50 years of age with microhematuria as well as in younger patients with microhematuria who have risk factors for urinary tract malignancy (e.g., tobacco use, cyclophosphamide treatment, prolonged exposure to aniline dye).

5. A 69-year-old woman comes to the emergency department because of a 3-hour history of pain in her left wrist. She was cleaning a table when she slipped forward and fell onto a flexed hand. Medical history is remarkable for hypertension, hypercholesterolemia, and osteoporosis. Current medications include perindopril, pitavastatin, and alendronate. She has smoked one pack of cigarettes daily for 50 years. Examination shows warmth, tenderness, and edema of the left wrist. Range of motion is decreased due to pain. An x-ray series of the left arm shows multiple fragmentations at the distal radioulnar joint and an

intraarticular oblique fracture with volar displacement of the distal fragment of the radius. Which of the following is the most appropriate next step in management?

Tip: This patient's x-ray findings of an intraarticular fracture with volar displacement of the distal fragment of the radius indicate a complex fracture.

Internal fixation with intramedullary nailing
13%

Sling and swathe splint
4%

Closed reduction with percutaneous pinning
14%

Open reduction internal fixation
67%
Open reduction internal fixation (ORIF) and other forms of operative management are indicated for complicated distal radius fractures (i.e., comminuted, intraarticular, severely angulated or foreshortened, or unstable after reduction). Osteoporosis, which this patient has, is a risk factor for both comminuted and distal radius fractures, complicates management and recovery, and is an indication for ORIF. Barring the development of any concerning neurovascular findings (e.g., decreased sensation due to compression of the median nerve, absent radial pulse), uncomplicated distal radius fractures can be managed conservatively.

Hanging-arm cast
2%

6. A 60-year-old man comes to the physician for a routine health maintenance examination. Over the past year, he has had problems initiating urination and the sensation of incomplete bladder emptying. He has a history of hypertension and hypercholesterolemia. He has smoked one pack of cigarettes daily for the past 40 years. He does not drink alcohol. His medications include lisinopril, atorvastatin, and daily aspirin. Vital signs are within normal limits. Physical examination shows a pulsatile abdominal mass at the level of the umbilicus and a bruit on auscultation. Digital rectal examination shows a symmetrically enlarged, smooth, firm, nontender prostate with rubbery texture. Laboratory studies are within normal limits. Which of the following is the most appropriate next step in management?

Tip: This patient has a history of smoking, hypercholesterolemia, and arterial hypertension and presents with a pulsatile abdominal mass and a bruit on auscultation. These features are suggestive of an abdominal aortic aneurysm (AAA). He does not have abdominal, back, or flank pain, flank ecchymoses, or signs of hemodynamic instability that would suggest rupture.

CT scan of the abdomen with contrast
18%
CT angiography of the abdomen and pelvis is appropriate for hemodynamically stable patients with confirmed or suspected symptomatic AAA. This test provides a detailed assessment of the location, size, and extent of the aneurysm, as well as the involvement of branch vessels, presence of a thrombus, and/or rupture. Signs of symptomatic AAA include abdominal, back, or flank pain, flank ecchymoses, and signs of aortic fistula (e.g., heart failure, upper

gastrointestinal bleeding), which this patient does not have. A different step in management is more appropriate for asymptomatic AAA.

Catheter arteriography
1%
Intraoperative catheter arteriography of the aorta can be used to assess the intraluminal space and the presence of a leak after repair of an AAA. However, it has limited use during diagnostic workup, as it only assesses the aortic lumen and cannot distinguish between the vessel wall and a blood clot in an aneurysm (and thus cannot estimate aneurysm size).

Prostate biopsy
1%
A prostate biopsy would be appropriate for a patient with a high suspicion for prostate cancer (e.g., presence of constitutional symptoms, terminal hematuria). However, this patient's urinary symptoms (hesitancy and incomplete voiding), in combination with a digital rectal examination showing a symmetrically enlarged, smooth, firm, nontender prostate with rubbery texture, are consistent with benign prostatic hyperplasia. This does not merit urgent management at this time, particularly in this patient with findings suspicious for an AAA.

PSA level testing
7%
Elevated prostate-specific antigen (PSA) levels are a nonspecific finding in several conditions that affect the prostate, including prostate cancer and benign prostatic hyperplasia (BPH). This patient's urinary symptoms (hesitancy and incomplete voiding), in combination with a digital rectal examination showing a symmetrically enlarged, smooth, firm, nontender prostate with rubbery texture, are consistent with BPH. This does not merit urgent management at this time, particularly in this patient with findings suspicious for an AAA.

Abdominal ultrasonography
71%
Patients with a suspected asymptomatic AAA should undergo abdominal ultrasonography to confirm the diagnosis (dilatation of the aorta ≥ 3 cm) and evaluate the extent of disease, including location and size of the aneurysm, presence of a blood clot, and presence of comorbid iliac artery aneurysms. The sensitivity and specificity of abdominal ultrasonography for AAA are nearly 100%. After the diagnosis is established, management strategies depend on the risk factors for rupture (e.g., aneurysm diameter and rate of expansion).

Renal arteriography
2%
Renal arteriography is the gold standard for diagnosing renal artery stenosis (RAS), which can also present with an abdominal bruit. However, additional clinical features include treatment-resistant hypertension and hypokalemia (from elevated aldosterone levels) and elevated serum creatinine concentration, which this patient does not have. Other diagnostic methods for workup of RAS include renal ultrasonography, CT angiography, and MR angiography.

7. A 23-year-old woman comes to the physician for a routine health maintenance examination. She reports that she feels well. Upon questioning, she mentions that she has had an occasional dry cough and recurrent hoarseness over the past 6 months. She does not smoke and has not lost weight. Physical examination shows no abnormalities. Laboratory

studies are within the reference ranges. An x-ray of the chest shows a mass that projects across the right hilum. A CT scan of the chest is shown. Which of the following is the most likely diagnosis?

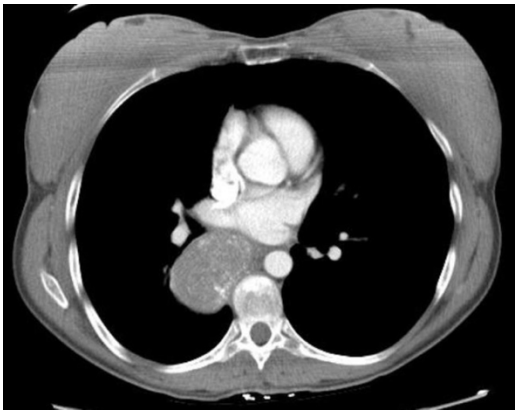

Tip: The CT scan shows that the mass is located in the posterior mediastinum.

Esophageal cancer
14%
Esophageal cancer often manifests as a middle and/or posterior mediastinal mass. Affected patients typically present with dysphagia and weight loss; hoarseness would be uncommon. In addition, esophageal cancer usually manifests in middle to late adulthood (45–75 years old) rather than young adulthood.

Thymoma
39%
Although a thymoma may manifest with cough due to mass effect, it develops in the anterior mediastinum. This patient's signs are confined to the posterior mediastinum.

Neurofibroma
24%
Neurogenic tumors (e.g., neurofibromas and schwannomas) account for the majority of posterior mediastinal masses (~ 60%). Intrathoracic neurofibromas usually manifest in young adults (20–30 years), typically with chest pain caused by mass effect upon the chest wall. Although neurofibromas are benign, large masses can cause a dry cough (due to compression of the lung), hoarseness (due to compression of the recurrent laryngeal nerve), or dysphagia (due to compression of the vagus nerve). As in this case, constitutional symptoms (i.e., fever and weight loss) are usually absent and laboratory studies are typically normal.

Teratoma
15%
Teratomas are benign germ cell tumors that are usually asymptomatic but can cause cough due to mass effect. Unlike here, they are generally found in the anterior mediastinum and have CT findings of a heterogeneous mass containing multiple tissue types (e.g., fat, fluid, bone).

Aortic aneurysm
7%

Intrathoracic cardiovascular structural anomalies (e.g., aortic aneurysm, pulmonary artery aneurysm, or vascular ring) usually manifest as masses in the middle and/or posterior mediastinum. Aortic aneurysm usually manifests as left-sided masses, not the right-sided mass seen in this case. In addition, while aortic aneurysms are better visualized on contrast-enhanced chest CT, the mass in this patient is clearly visualized as a separate entity from the intrathoracic aorta.

8. A 10-month-old boy is brought to the physician by his mother because of a 1-week history of a painless bulge in the right groin. His mother says that the bulge is only intermittently visible and increases in size with coughing. He was born via cesarean delivery at 32 weeks' gestation because of premature rupture of membranes. He has no history of serious illness and receives no medications. He appears well. Growth and development are appropriate for age. He is at the 50th percentile for length and weight. Temperature is 37.1°C (98.8°F), pulse is 130/min, and respirations are 40/min. Physical examination shows a 2 x 2-cm nontender right inguinal mass that is manually reducible with gradual pressure. Ultrasonography of the groin in supine position shows widening of the deep inguinal ring. Which of the following is the most appropriate next step in management?

Tip: An intermittent inguinal mass that increases in size with raised intraabdominal pressure is characteristic of an indirect inguinal hernia.

Hospital admission for immediate surgery
2%

Parental training on manual reduction
10%

Referral to a pediatric surgeon
40%

Surgical repair is indicated in all children with inguinal hernia. In asymptomatic patients, surgery should be performed within 14 days of diagnosis to avoid complications (e.g., incarcerated hernia). Therefore, emergency surgery is not required but referral should be obtained promptly. While waiting for elective surgery, parental training on signs and symptoms of incarceration is important because an incarcerated or strangulated hernia requires immediate action.

Indirect inguinal hernias are most common among male infants and infants who are born prematurely, as they mostly result from incomplete obliteration of the processus vaginalis during fetal development. Some hernias, despite being present since birth, do not become symptomatic until adulthood.

MRI of the abdomen and pelvis
2%

Reassurance and follow-up only
45%

9. Two weeks after undergoing coronary artery bypass surgery for acute myocardial infarction, a 62-year-old man comes to the physician because of a 4-day history of fever, sharp chest

pain, and progressive fatigue. Initially, the pain was only present when he was lying supine, but now it is constant and only subsides when he leans forward. He has hypertension and mild mitral regurgitation. He has smoked one pack of cigarettes daily for 44 years but quit prior to surgery. Current medications include aspirin, clopidogrel, metoprolol, captopril, and atorvastatin. His temperature is 38.3°C (102°F), pulse is 84/min and regular, respirations are 16/min, and blood pressure is 132/86 mm Hg. During inspiration, the patient's blood pressure drops to 117/80 mm Hg. On physical examination, there are jugular venous pulsations 4 cm above the sternal angle. Heart sounds are faint. There is 2+ edema in the lower extremities. Which of the following additional findings is most likely to be present in this patient?

This patient's presentation of fatigue, fever, and chest pain that is relieved by leaning forward two weeks after cardiothoracic surgery indicates postpericardiotomy syndrome. This syndrome can be complicated by pericardial effusion and cardiac tamponade.

Increased mean aortic pressure
2%

Left ventricular volume overload
7%

Increased right ventricular compliance
3%

Decreased left ventricular preload
63%
Postpericardiotomy syndrome typically manifests 1–6 weeks after cardiothoracic surgery as a result of an autoimmune inflammatory process in the pericardium. This syndrome may be accompanied by pericardial effusion, which can lead to cardiac tamponade, manifesting with muffled heart sounds and pulsus paradoxus. Fluid accumulation in the pericardial space leads to compression of the heart (especially the right ventricle because of its thin wall). This compression results in a shift of the interventricular septum toward the left ventricle and impaired left ventricular diastolic filling (decreased preload). Cardiac output subsequently decreases and symptoms of backward heart failure (e.g., peripheral edema and jugular venous distension due to right-sided heart failure) and forward heart failure (e.g., progressive fatigue) develop.

Pericardial effusion causing cardiac tamponade is a life-threatening condition that requires drainage of the pericardial fluid (e.g., using pericardiocentesis).

Decreased pressure in the pericardial space
2%

Decreased right ventricular contractility
22%

10. Six days after being admitted to the hospital for cholecystectomy, a 56-year-old woman has high-grade fevers, chills, malaise, and generalized weakness. She has been hospitalized twice in the last year for acute cholecystitis. She had a molar extraction around 2 weeks ago. Her last colonoscopy was 8 months ago and showed a benign polyp that was removed. She has mitral valve prolapse, hypertension, rheumatoid arthritis, and hypothyroidism.

Current medications include metformin, rituximab, levothyroxine, and enalapril. Her temperature is 38.3°C (101°F), pulse is 112/min, and blood pressure is 138/90 mm Hg. Examination shows painless macules over her palms and soles and linear hemorrhages under her nail beds. The lungs are clear to auscultation. There is a grade 3/6 systolic murmur heard best at the apex. Blood is drawn and she is started on intravenous antibiotic therapy. Two sets of blood cultures grow coagulase-negative staphylococci. Echocardiography shows a large oscillating vegetation on the mitral valve and moderate mitral regurgitation. Which of the following is the strongest predisposing factor for this patient's condition?

Tip: Acute onset of high-grade fever, chills, splinter hemorrhages, and Janeway lesions (painless macules on palms and soles) in combination with a valvular vegetation on echocardiography and two positive blood cultures suggest acute infective endocarditis (IE). The coagulase-negative Staphylococcus species most commonly associated with IE is Staphylococcus epidermidis.

Predamaged heart valve
49%
Individuals with predamaged heart valves (e.g., mitral valve prolapse) are at increased risk for developing IE. However, the organisms most commonly associated with IE in predamaged valves are viridans streptococci, which are gram-positive streptococci. Viridans streptococci typically cause subacute IE, which is characterized by a slow progression (weeks to months) and less severe constitutional symptoms (e.g., low fever may occur but is often absent).

Colonic polyp
1%
A colonic polyp may be benign or malignant. Malignant colonic polyps can develop into colon cancer. IE due to an infection with Streptococcus gallolyticus (formerly known as Streptococcus bovis biotype I, a group D Streptococci) is associated with an increased incidence of colonic neoplasms. However, this patient had coagulase-negative staphylococci in her blood cultures and a colonoscopy 8 months ago showed a benign polyp, all of which make this risk factor unlikely.

Recent dental procedure
21%
Dental procedures are an important risk factor for subacute IE, especially in patients with predamaged native valves (mainly the mitral valve) and in patients with prosthetic valves (≥ 60 days after surgery). The most common pathogens in subacute IE are viridans streptococci (gram-positive streptococci), a common commensal of the oropharynx. Subacute IE has an insidious onset, is characterized by slow progression (weeks to months), and has less severe constitutional symptoms (e.g., low fever may occur but is often absent). Although this patient has a history of a predamaged native valve (mitral valve prolapse), she presents with acute IE and has severe symptoms, which make the diagnosis of subacute IE due to an infection with viridans streptococci unlikely.

Immunosuppression
4%
Immunosuppression is an important risk factor for IE, particularly with atypical pathogens such as Candida species and Aspergillus fumigatus. This patient takes rituximab, which is in fact considered an immunosuppressive medication. IE caused by Candida species and Aspergillus fumigatus occurs especially following cardiosurgical interventions. However, infection with

coagulase-negative staphylococci, as in this patient, is more often associated with a different risk factor than immunosuppression.

Infected peripheral venous catheter
25%
This patient with acute IE has most likely acquired S. epidermidis bacteremia through an infected peripheral venous catheter during her hospital stay. S. epidermidis has the ability to adhere to foreign bodies (e.g., intravenous catheters, pacemakers) and subsequently form a biofilm. The pathogen accounts for about 30% of health care-associated bloodstream infections and is a common cause of IE in patients with prosthetic heart valves (see "Pathogens causing infective endocarditis" table).

Because coagulase-negative staphylococci often colonize the skin of healthy individuals, they are commonly found in contaminated blood cultures, and their presence is not always clinically significant. Repeat cultures and evaluation of the culture results in accordance with clinical findings are therefore recommended.

11. Two weeks after undergoing allogeneic stem cell transplant for multiple myeloma, a 55-year-old man develops a severely pruritic rash, abdominal cramps, and profuse diarrhea. He appears lethargic. Physical examination shows yellow sclerae. There is a generalized maculopapular rash on his face, trunk, and lower extremities, and desquamation of both soles. His serum alanine aminotransferase is 115 U/L, serum aspartate aminotransferase is 97 U/L, and serum total bilirubin is 2.7 mg/dL. Which of the following is the most likely underlying cause of this patient's condition?

Tip: This patient developed a desquamating pruritic rash, diarrhea with abdominal cramping, and evidence of liver damage (scleral jaundice, elevated transaminases) shortly after a stem cell transplantation, which is concerning for graft-versus-host disease (GvHD).

Donor T cells in the graft
61%
During allogeneic stem cell transplantation, donor T cells can perceive host tissue as a foreign antigen and mount an immune response, resulting in acute GvHD within 100 days of transplantation. It commonly affects the skin, mucosa, liver, and intestine; thus, patients present with maculopapular rash, diarrhea, jaundice, and hepatosplenomegaly, as observed in this patient.

Newly formed anti-HLA antibodies
12%
Newly formed anti-HLA antibodies mediate a humoral immune response in acute graft rejection. Antigen-antibody complexes activate the complement cascade, which mediates tissue injury; hence, complement fragments (C4d) can be observed upon graft tissue staining. Patients with acute graft rejection present with fever, pain in the graft region, and graft vessel vasculitis within 6 months of transplantation. Although this patient presented within 2 weeks of transplantation, he has involvement of intestine, liver, and skin, making acute graft rejection unlikely.

Proliferating transplanted B cells
4%
Although proliferating transplanted B cells have been shown to have a role in chronic GvHD in studies with animal models, its role in patients with allogeneic stem cell transplantation is not well defined. Chronic GvHD is observed 100 days after transplantation and presents with clinical

features of chronic enteritis, chronic sicca syndrome, bronchiolitis obliterans, liver dysfunction, and polymyositis.

Activated recipient T cells
18%
Exposure to graft MHC alloantigen can activate recipient T cells, which orchestrates a type 4 hypersensitivity reaction (cell-mediated immune response), that develops into acute graft rejection within weeks to months. Patients present with fever, graft tissue swelling, generalized deterioration, and lymphocytic infiltration of graft vessels; although this patient presented within 2 weeks of transplantation, his symptoms are not confined to the transplanted tissue.

Preformed cytotoxic anti-HLA antibodies
6%
Preformed cytotoxic anti-HLA antibodies react to graft class 1 HLA antigen and mediate hyperacute graft rejection, which is commonly seen in cases with donor recipient ABO incompatibility. Antigen-antibody complexes activate the complement system (type 2 hypersensitivity reaction), leading to thrombus formation and graft ischemia. Patients present with intraoperative graft swelling and can develop systemic inflammatory response syndrome within minutes to hours, unlike this patient who presented 2 weeks after transplantation with maculopapular rash, diarrhea, and features of liver injury.

12. A 42-year-old man comes to the emergency department because of a 1-week history of palpitations and tingling in his hands. He has also had severe cramping in his hands, feet, and abdomen during this period. Three months ago, he was hospitalized for acute pancreatitis. He discharged himself against medical advice at that time. There is no family history of illness. He does not smoke. He drinks two to three beers and a pint of vodka daily. He has a history of using intravenous heroin. He is only oriented to place and person. Temperature is 37.1°C (98.8°F), pulse is 90/min, and blood pressure is 110/96 mm Hg. There is a carpopedal spasm while measuring his blood pressure. Cardiopulmonary examination shows no abnormalities. Deep tendon reflexes are 4+ bilaterally. Neurologic examination shows no focal findings. Which of the following is the most appropriate pharmacotherapy?

Tip: The presence of paresthesias, muscle cramps, and Trousseau sign is highly suggestive of hypocalcemia.

Sodium bicarbonate
12%
Sodium bicarbonate is the antidote for overdose from barbiturates, salicylates, and tricyclic antidepressants, among other drugs. It works by alkalizing the urine and enhancing the excretion of these substances. Barbiturate overdose manifests with respiratory depression and a decreased level of consciousness. The overdose of salicylates causes tinnitus, hyperventilation, vomiting, and abdominal pain. Tricyclic antidepressant overdose causes an anticholinergic toxidrome with fever, mydriasis, confusion, and tachycardia. This patient's presentation is inconsistent with any of these overdoses.

Lorazepam
7%
Benzodiazepines such as lorazepam are used to treat alcohol withdrawal. This patient may have a history of excessive alcohol intake, but he does not currently have any symptoms of

alcohol withdrawal such as anxiety, diaphoresis, tachycardia, tremors, hallucinations, or seizures.

Magnesium sulfate
53%
Chronic heavy alcohol use is associated with increased excretion of magnesium with urine and is one of the most common causes of hypomagnesemia-induced hypocalcemia. Because magnesium plays an important role in the production and release of PTH, patients with hypomagnesemia develop decreased levels of, and tissue resistance to PTH, both of which result in hypocalcemia. Therefore, patients with hypomagnesemia-induced hypocalcemia require magnesium supplementation before calcium replacement therapy can be initiated.

Fomepizole
3%
Fomepizole is used to treat alcohol intoxication, particularly for toxic alcohols such as ethylene glycol or methanol. This patient does not present with classic symptoms of alcohol intoxication such as slurred speech, nausea and vomiting, flushed skin, confusion, or ataxia.

Naloxone
1%
Naloxone is used to treat opioid overdose. While this patient does have a history of intravenous heroin use, he does not currently have any signs of opioid overdose (i.e., miosis, respiratory depression, or decreased level of consciousness).

Thiamine
24%
Thiamine is used to treat Wernicke-Korsakoff syndrome caused by long-standing vitamin B1 deficiency. This patient is only oriented to place and person, but further symptoms associated with Wernicke-Korsakoff syndrome are missing, such as ophthalmoplegia, ataxia, or confabulations.

13. A 65-year-old man is admitted to the hospital for elective surgical repair of a right-sided inguinal hernia. His medical history is remarkable for hypertension and colorectal carcinoma, for which he underwent right-sided hemicolectomy 7 years ago. His medications are metoprolol and lisinopril. Physical examination shows a soft and reducible mass in the patient's right inguinal region and a well-healed midline scar. The patient is scheduled for an open hernioplasty on the next day. The attending surgeon who will perform the procedure expects no significant complications. A fourth-year medical student who is on rotation in the surgical ward asks if she may scrub in and participate as a second assistant in the procedure. She has sufficient experience in the operating room from previous clerkships. Which of the following is the most appropriate action by the attending surgeon?

Tip: Student participation in patient care is an important method for developing critical competencies (e.g., empathy, clinical thinking, patient management).

Allow the student to observe the procedure only
3%

Allow the student to participate under supervision
7%

Introduce the student as a colleague and inform the patient about her participation in the procedure
5%

Ask the student to inform the patient about her participation in the procedure
5%

Disclose the student's identity and training status to the patient and ask for consent
80%

Before surgery, a patient (or their surrogate) should be briefed about the risks, benefits, and alternatives to the procedure and authorize the plan. A physician should balance their responsibility to train medical students with their obligation to provide optimal care (nonmaleficence) while upholding the rights of the patient (autonomy). If a student wishes to assist in surgery, the attending surgeon should inform the patient about the student's identity and level of training, and the patient must give informed consent for participation. As with any other decision, the patient has the right to refuse student involvement in their care at any time.

14. A 73-year-old man comes to the physician because of a 4-kg (9-lb) weight loss over the last month. During this time he has not been able to eat more than one bite without coughing immediately and sometimes he regurgitates food through his nose. His symptoms are worse with liquids. One month ago he had a stroke in the right middle cerebral artery. He has a history of hypertension, type 2 diabetes mellitus, and hyperlipidemia. Current medications include aspirin, amlodipine, metformin, and simvastatin. Examination of the oropharynx, chest, and abdomen shows no abnormalities. Neurological examination shows facial drooping on the left and decreased strength in the left upper and lower extremities. Which of the following is the most appropriate next step in management?

Tip: Dysphagia early in the swallowing process that worsens with liquids, coughing, and nasal regurgitation indicate oropharyngeal dysphagia. Oropharyngeal dysphagia commonly affects patients with neuromuscular dysfunction, such as this patient who recently had a stroke.

Videofluoroscopy
43%
A videofluoroscopic modified barium swallow is considered the test of choice for evaluating oropharyngeal dysphagia. It involves direct visualization of the entire swallowing process using continuous x-rays and barium contrast. This diagnostic test evaluates the patient's risk of aspiration and determines whether the patient might benefit from supervised feedings, swallow rehabilitation therapy, and/or enteral nutrition.

CT scan of the neck
3%

Esophagram
15%

Esophageal manometry
23%

Transnasal laryngoscopy

4%

Upper endoscopy
12%

15. A 73-year-old woman is brought to the emergency department because of a 2-day history of diffuse abdominal pain, nausea, and vomiting. She has hypertension, congestive heart failure, atrial fibrillation, and osteoarthritis. She underwent an exploratory laparotomy for an ovarian mass a year ago where a mucinous cystadenoma was excised. Her medications include aspirin, nifedipine, lisinopril, metoprolol, warfarin, and acetaminophen as needed for pain. She does not drink alcohol or smoke cigarettes. She appears ill and disoriented. Her temperature is 37.9°C (100.3°F), pulse is 110/min and irregular, respirations are 16/min, and blood pressure is 102/60 mm Hg. Examination shows diffuse tenderness to palpation of the abdomen. The abdomen is tympanitic on percussion. Bowel sounds are hyperactive. The lungs are clear to auscultation bilaterally. There is a soft crescendo-decrescendo murmur best auscultated in the right second intercostal space. Laboratory studies show:

Hemoglobin 10.2 g/dL
Leukocyte count 14,000/mm3
Platelet count 130,000/mm3
Prothrombin time 38 seconds
INR 3.2
Serum
Na+ 132 mEq/dL
K+ 3.6 mEq/dL
Cl- 102 mEq/dL
HCO3- 19 mEq/dL
Urea nitrogen 44 mg/dl
Creatinine 2.1 mg/dL
Lactate 2.8 mEq/dL (N= 0.5–2.2 mEq/dL)

An x-ray of the abdomen shows multiple centrally located dilated loops of gas-filled bowel. There is no free air under the diaphragm. A nasogastric tube is inserted and IV fluids and empiric antibiotic therapy are started. An emergency exploratory laparotomy is planned. Which of the following is the next best step in management?

Tip: Diffuse abdominal pain, nausea, vomiting, abdominal tenderness, hyperactive bowel sounds, elevated serum lactate, leukocytosis, prerenal kidney injury, and multiple loops of gas-filled bowel on x-ray are consistent with small bowel obstruction with possible bowel ischemia. Although this patient requires immediate surgery, she has an increased bleeding risk, as indicated by prolonged prothrombin time (PT) and elevated INR.

Administer low molecular weight heparin
10%
Low molecular weight heparin (LMWH) should not be administered in this patient, as she is already over-anticoagulated with an elevated INR of 3.2 from warfarin therapy. The priority is to reverse her anticoagulation before the emergency surgery to reduce the risk of bleeding. Additionally, LMWH should be used with caution in patients with impaired renal function, such as this patient with a creatinine level of 2.1 mg/dL, since renal impairment decreases LMWH clearance and further increases the risk of bleeding.

Administer unfractionated heparin
7%
Unfractionated heparin (UFH) is commonly used for risk reduction of peri- and postoperative thrombotic events. However, this patient is currently on oral anticoagulation with warfarin and has a higher risk of excessive bleeding during surgery than thrombotic events. Treatment with UFH perioperatively would further increase the risk of bleeding in this patient. UFH can be administered postoperatively until therapeutic anticoagulation is resumed and on target level.

Administer protamine sulfate
4%
Protamine sulfate is used for heparin neutralization and low molecular weight heparin overdose. This patient's history and laboratory studies, do not suggest heparin use as a reason for her impaired coagulation; protamine sulfate would not be indicated.

Administer vitamin K
14%
Administration of vitamin K is used to prevent and treat hypoprothrombinemia caused by vitamin K antagonists such as warfarin. Although this patient requires immediate reversal of her anticoagulation in order to undergo surgery, the effect of vitamin K takes at least 1–2 hours with a peak after 12–24 hours if administered intravenously, and even longer if administered orally. Therefore, vitamin K alone would not be the appropriate therapy for this patient.

Administer prothrombin complex concentrate and vitamin K
59%
Prothrombin complex concentrate and vitamin K can both be used for anticoagulation reversal in patients with decreased vitamin K-dependent coagulation factors (factors II, VII, IX, and X), e.g., due to warfarin intake. Administration of vitamin K alone would be insufficient, as it takes hours to days to produce further coagulation factors and take full effect. Additional administration of prothrombin complex concentrate is therefore indicated as it replaces those coagulation factors needed to immediately establish sufficient coagulation for surgery.

After surgery, this patient requires anticoagulant treatment to decrease her thrombotic risk. In this patient with reduced renal function, administering unfractionated heparin would be appropriate.

Administer platelet concentrate
3%
Platelet concentrate can be administered either therapeutically to treat active bleeding or prophylactically to prevent active bleeding in patients with thrombocytopenia. Indications include actively bleeding patients or a platelet count of < 50,000/mm3 for major surgeries, or < 100,000/mm3 for neurosurgical procedures. Because this patient's laboratory studies reveal only slight thrombocytopenia with a platelet count of 130,000/mm3, platelet concentrates are not indicated.

Administer recombinant activated factor VII
3%
Recombinant activated factor VII is used in patients with isolated factor VII deficiency. In other patients, administration of recombinant activated factor VII should be avoided because of the significant risk of arterial thrombosis. This patient's history suggests warfarin therapy and not factor VII deficiency as the cause of her impaired coagulation.

16. A 69-year-old man comes to the physician because of progressive difficulty swallowing and a 5-kg (11-lb) weight loss over the past 3 months. He first had trouble swallowing solid foods and then also developed difficulty swallowing liquids over the past week. Endoscopy shows a large mass 3 cm proximal to the esophagogastric junction. Biopsy of the mass shows significant distortion of glandular architecture. Which of the following is the strongest predisposing factor for this patient's condition?

Tip: Visualization of a mass in the distal third of the esophagus with histopathologic examination that shows distorted glandular architecture confirms a diagnosis of esophageal adenocarcinoma.

Atrophic gastritis
22%
Atrophic gastritis increases the risk of esophageal squamous cell carcinoma (eSCC). Bacterial overgrowth in the achlorhydric stomach generates reactive carcinogenic nitrogen products that can induce eSCC transformation. Although eSCC manifests with dysphagia and weight loss, as seen in this patient, a biopsy would show pathognomonic circular areas of keratinization. Atrophic gastritis is not associated with an increased risk of esophageal adenocarcinoma.

Consumption of hot liquids
12%
Chronic consumption of hot liquids and food increases the risk of esophageal squamous cell carcinoma (eSCC) due to thermal damage of the esophageal mucosa. The resulting inflammation stimulates the production of reactive nitrogen species, which are carcinogenic. Although eSCC manifests with dysphagia and weight loss, as seen in this patient, a biopsy would show pathognomonic circular areas of keratinization. Consumption of hot liquids is not associated with an increased risk of esophageal adenocarcinoma.

Chronic alcohol use
33%
Chronic and excessive alcohol consumption increases the risk of esophageal squamous cell carcinoma (eSCC). Although eSCC manifests with dysphagia and weight loss, as seen in this patient, biopsy findings would show pathognomonic circular areas of keratinization. While chronic alcohol use can cause gastroesophageal reflux disease, alcohol consumption has not been associated with an increased risk of esophageal adenocarcinoma. Moreover, another predisposing factor is more strongly associated with an increased risk of esophageal adenocarcinoma.

Visceral obesity
26%
Obesity is an important risk factor for esophageal adenocarcinoma. Although the exact mechanism is unknown, it is hypothesized that obesity increases the risk of adenocarcinoma by increasing the risk of reflux and via mechanisms independent of reflux. Gastroesophageal reflux disease induces metaplasia (Barrett esophagus), which can progress to adenocarcinoma. In addition, excessive visceral fat increases the risk of inflammation, the production of cytokines and growth factors, and insulin resistance, all of which are risk factors for carcinoma. Other risk factors for esophageal adenocarcinoma include smoking, achalasia, and certain diets (high in animal protein or cholesterol, low in fiber). Smoking and achalasia furthermore increase the risk of esophageal squamous cell carcinoma.

Consumption of cured meats
7%
Chronic consumption of nitrosamine-rich foods (e.g., bacon, other cured meats, pickles, alcohol) is associated with an increased risk of esophageal squamous cell carcinoma (eSCC). Although eSCC manifests with dysphagia and weight loss, as seen in this patient, a biopsy would show pathognomonic circular areas of keratinization. Consumption of cured meats is not associated with an increased risk of esophageal adenocarcinoma.

17. A 72-year-old man comes to the emergency department because of severe, acute, right leg pain for 2 hours. The patient's symptoms started suddenly while he was doing household chores. He has no history of leg pain at rest or with exertion. He has hypertension treated with ramipril. He appears uncomfortable. His temperature is 37.4°C (99.3°F), pulse is 105/min and irregular, and blood pressure is 146/92 mm Hg. The right lower extremity is cool and tender to touch. A photograph of the limb is shown. Femoral pulses are palpable bilaterally; popliteal and pedal pulses are decreased on the right side. Sensation to pinprick and light touch and muscle strength are decreased in the right lower extremity. Which of the following is most likely to have shown the underlying cause prior to the onset of this patient's current symptoms?

Tip: Pain, pallor, pulselessness, paralysis, paresthesia, and poikilothermia (6 Ps) are hallmarks of acute limb ischemia (ALI).

Gadolinium-enhanced MRA of the legs
3%
Gadolinium-enhanced magnetic resonance angiography (MRA) of the legs is a confirmatory test for ALI and is useful for identifying arterial thrombi and dissections as an underlying etiology of ALI. It would not, however, help to confirm the most likely underlying source of this patient's ALI.

Echocardiography
41%
Echocardiography can be used to visualize an atrial thrombus, which can develop as a complication of atrial fibrillation (Afib). This patient's irregular pulse is suggestive of Afib. The atrial thrombus (or parts of it) may dislodge and embolize into the systemic circulation, thereby leading to arterial occlusion and subsequent ischemia. The most common location of arterial occlusion due to arterial embolism is the femoropopliteal artery.

ALI is commonly caused by thrombosis secondary to peripheral artery disease (PAD); however, the absence of preexisting claudication in this case makes PAD a less likely diagnosis.

Doppler ultrasonography of the legs
17%
Doppler ultrasonography of the legs is the best initial test for detecting arterial and venous thrombosis and assessing the severity of ALI. It would not, however, help to confirm the most likely underlying cause of this patient's current symptoms.

Digital subtraction angiography
10%
Digital subtraction angiogram (DSA) is an imaging modality used to diagnose ALI. It should only be performed if treatment can be delayed for further imaging without posing a threat to the extremity. DSA is useful for identifying arterial occlusions or dissections as an underlying etiology of ALI and facilitates immediate therapeutic intervention, e.g., catheter-directed thrombolysis. DSA would not, however, help to confirm the most likely underlying source of this patient's ALI.

Manometry of the right leg
1%
Needle manometry of the limb is the diagnostic test of choice for suspected compartment syndrome, which typically occurs secondary to trauma (e.g., expanding hematoma, closed fracture, crush injury) and leads to extrinsic compression of the arteries. Symptoms (the 6 Ps) are difficult to distinguish from those caused by acute intraluminal occlusion of an artery. However, manometry would not help to identify the underlying etiology of ALI.

Ankle-brachial index
28%
The ankle-brachial index is primarily used to diagnose peripheral artery disease (PAD), but it is also used to assess ALI. Values < 0.4 indicate severe occlusion and ischemia. This patient has no history of claudication or trophic changes to his lower extremities, making PAD unlikely. Although this test quantifies the severity of arterial occlusion in ALI, it does not help to confirm the underlying etiology.

18. Three days after undergoing an open cholecystectomy, a 76-year-old man is evaluated for confusion and fever. He has hypertension, type 2 diabetes mellitus, and chronic obstructive pulmonary disease. He smoked 1 pack of cigarettes daily for 40 years but quit 1 year ago. He does not drink alcohol. Prior to admission to the hospital, his medications included lisinopril, metformin, and ipratropium. He appears acutely ill and lethargic. His temperature is 39.5°C (103.1°F), pulse is 108/min, respirations are 22/min, and blood pressure is 110/84 mm Hg. He is oriented to person but not to place and time. Examination shows a 10-cm subcostal incision that appears dry and mildly erythematous; there is tenderness to palpation of the lower abdomen without guarding or rebound. Pulmonary examination shows scattered expiratory wheezing throughout both lung fields and no crackles. The remainder of the physical examination shows no abnormalities. A urinary catheter is in place and urine output is normal. Which of the following is most likely to establish the diagnosis?

Tip: Fever, altered mental status, tachycardia, and tachypnea raise concern for postoperative sepsis. Certain postoperative measures that help to prevent sepsis may have been missed in this patient.

Wound swab for Gram stain and culture
8%
A wound swab for Gram stain and culture is used to diagnose incisional surgical site infection (SSI), which can cause postoperative fever and sepsis. Manifestations of SSI include localized swelling, tenderness, erythema, and purulent discharge from the incision, whereas this patient's surgical wound is dry and only mildly erythematous. Moreover, SSI is uncommon during the first four days after surgery.

Chest x-ray
22%
Pneumonia, which can be diagnosed on chest x-ray, is a common cause of early postoperative fever and the most common source of sepsis. However, this patient does not have further features of pneumonia, such as productive cough, dyspnea, pleuritic chest pain, and typical auscultation findings (e.g., decreased breath sounds, crackles). The scattered bilateral wheezing is likely related to his chronic obstructive pulmonary disease. While underlying pneumonia cannot be definitively ruled out, it is not the most likely cause of sepsis in this case.

Peritoneal fluid analysis
7%
Peritoneal fluid analysis can be used to diagnose biliary leak following cholecystectomy. Biliary leak can manifest with abdominal discomfort and fever, but jaundice, nausea, and vomiting are also typically seen. If secondary bacterial peritonitis develops, patients present with signs and symptoms of sepsis; however, peritoneal signs such as rebound tenderness and/or guarding are also expected. Diagnosis of postoperative biliary leak is usually established with imaging (e.g., CT abdomen, HIDA scan) rather than peritoneal fluid analysis alone. Finally, biliary leak is a typical complication of laparoscopic rather than open cholecystectomy.

Urine culture
50%
Catheter-associated urinary tract infections (CAUTIs) are a common cause of postoperative fever and sepsis in patients with indwelling urinary catheters. Symptoms are often nonspecific (e.g., fever, altered mental status, lower abdominal pain), particularly in older patients. Urine culture as well as two sets of blood cultures should ideally be obtained before initiating empiric broad-spectrum antibiotic therapy (e.g., imipenem plus vancomycin) in order to identify the causative organism and determine antibiotic susceptibility. This patient's qSOFA score of 2 (respiratory rate ≥ 22/min and altered mental status) indicates that he is at high risk of in-hospital mortality due to sepsis and should be admitted to the intensive care unit. Complete evaluation for organ dysfunction, continuous cardiac and respiratory monitoring, as well as frequent reassessments of hemodynamic parameters and serial serum lactate, are indicated.
In patients undergoing surgery not involving the urinary tract, urinary catheters should be removed as soon as possible to prevent CAUTIs, preferably within 24 hours postoperatively.

Abdominal CT
14%
Abdominal CT scan can be used to diagnose postoperative complications such as organ or space surgical site infection (e.g., intraabdominal abscess) and biliary leak. While an abscess can manifest with fever and abdominal pain, the tenderness is usually located in the region where surgery was performed. Moreover, surgical site infections most often occur ≥ 4 days after

surgery. Biliary leak can manifest with abdominal discomfort and fever, but jaundice, nausea, and vomiting are also typically seen. Both intraabdominal abscess and biliary leak can lead to secondary bacterial peritonitis, which can manifest with signs and symptoms of sepsis; however, peritoneal signs such as rebound tenderness and/or guarding are also expected.

19. A 65-year-old woman comes to the physician because of a 1-month history of persistent epigastric abdominal pain. She reports dull, aching pain that sometimes radiates to the back and wakes her up at night. She has had a 2-kg (4.4-lb) weight loss during this time. She has smoked a pack of cigarettes daily for the past 40 years. Her only medication is a calcium supplement. Her vital signs are within normal limits. She appears thin. Examination shows yellow discoloration of the sclera. Abdominal examination shows a nontender, enlarged gallbladder. The remainder of the examination shows no abnormalities. Laboratory studies show a total bilirubin of 9.8 mg/dL, direct bilirubin of 8.6 mg/dL, and an alkaline phosphatase of 560 IU/L. Abdominal ultrasonography shows dilation of the gallbladder and biliary and pancreatic ducts but no pancreatic or extrahepatic biliary lesions. Which of the following is the most appropriate next step in management?

Tip: Although ultrasonography does not show a pancreatic lesion, a combination of obstructive jaundice (↑ ALP, conjugated hyperbilirubinemia) with nontender enlarged gallbladder (Courvoisier sign), worsening epigastric pain that radiates to the back, weight loss, and a double duct sign in a 65-year-old patient with a history of smoking is highly suggestive of carcinoma of the pancreatic head.

Colonoscopy
0%
Colonoscopy is used to diagnose colon cancer, which would cause weight loss and abdominal pain. Smoking is a risk factor for colon cancer, and obstructive jaundice can occur in patients with liver metastasis. However, in the case of colon cancer, vague or diffuse abdominal pain is usually present, in contrast to this patient with epigastric pain, and dilation of the pancreatic ducts would not be expected. Instead, patients would have evidence of liver metastases on abdominal ultrasonography.

Plain abdominal CT
7%
Pancreatic carcinoma is typically ill-defined and often has the same tissue density as the surrounding normal pancreatic tissue. Plain abdominal CT scans, therefore, have poor sensitivity and specificity for pancreatic carcinoma.

Contrast-enhanced abdominal CT
47%
This was a challenging question! A contrast-enhanced abdominal CT is the investigation of choice to confirm pancreatic carcinoma and determine its resectability. On contrast CT, a pancreatic carcinoma typically appears as an ill-defined, hypodense mass (because it is poorly vascularized). If abdominal CT is inconclusive or shows a borderline resectable or unresectable tumor, endoscopic ultrasonography (EUS) and EUS-guided biopsy should be performed to histologically confirm the diagnosis. If metastases are absent and the tumor is resectable, surgical resection should be performed (e.g., Whipple procedure for pancreatic head tumors), followed by adjuvant chemotherapy. Borderline resectable tumors are treated with neoadjuvant chemotherapy followed by resection. Most often, though, metastases are discovered and/or the tumor is unresectable. Such patients are typically treated palliatively or can join a clinical trial.

This question is especially challenging because the patient's presentation resembles gallstone disease, which can also cause epigastric pain, obstructive jaundice, and dilation of both the biliary and pancreatic ducts if the stone is located near the ampulla of Vater. Also, such a stone may not be evident on ultrasound because ultrasonographic visualization of the most distal portions of the biliary tree is often not feasible. However, it is important to keep in mind that patients with gallstone disease will invariably have one or more of the following features on ultrasonography (especially in an exam question): thickening of walls of the biliary tree or gallbladder, pericystic fluid accumulation, scarring or shrinking of the gallbladder, and/or biliary sludge. Additionally, the epigastric pain is often worse after meals and does not radiate to the back. Lastly, Courvoisier sign usually makes gallstones an unlikely cause of biliary obstruction.

Endoscopic ultrasonography
4%
In a patient with suspected pancreatic cancer, endoscopic ultrasonography (EUS) and an EUS-guided biopsy would be performed only if the most appropriate next step is inconclusive, or if it shows a borderline resectable or unresectable tumor. Upper GI endoscopy and endoscopic ultrasonography would be indicated in the initial workup of a patient with suspected gastric cancer, which would manifest with weight loss and epigastric pain. Smoking is a risk factor for gastric cancer, and obstructive jaundice can occur in patients with liver metastasis. However, dilation of the pancreatic ducts would not be expected. Instead, evidence of liver metastases would be present on abdominal ultrasound.

Endoscopic retrograde cholangiopancreatography
41%
Although ERCP is not the most appropriate next step for this case, this was a good option to consider for two reasons:
• First, duct brushing cytology performed during ERCP has a high sensitivity for pancreatic head tumors and was performed in the past to confirm the diagnosis. However, ERCP is invasive and cannot define the extent of the tumor, which is important for determining its resectability. ERCP is therefore no longer performed in the initial diagnostic workup of pancreatic carcinoma.
• Second, after ultrasonography, some centers perform ERCP as the next step without obtaining any additional imaging if gallstone disease is suspected to be the underlying cause of biliary tract obstruction because the procedure is simultaneously diagnostic and therapeutic. Gallstone disease can cause epigastric pain, obstructive jaundice, and dilation of both the biliary and pancreatic ducts if the stone is located near the ampulla of Vater. Also, such a stone may not be evident on ultrasound because ultrasonographic visualization of the most distal portions of the biliary tree is often not feasible. However, it is important to keep in mind that patients with gallstone disease will invariably have one or more of the following features on ultrasonography (especially in an exam question): thickening of walls of the biliary tree or gallbladder, pericystic fluid accumulation, scarring or shrinking of the gallbladder, and/or biliary sludge. Additionally, the epigastric pain is often worse after meals and does not radiate to the back. Lastly, Courvoisier sign usually makes gallstones an unlikely cause of biliary obstruction.

20. A 68-year-old woman comes to the physician because of increasing heartburn for the last few months. During this period, she has taken famotidine several times a day without relief and has lost 10 kg (22 lbs). She has retrosternal pressure and burning with every meal. She has had heartburn for several years and took famotidine as needed. She has hypertension. She has smoked one pack of cigarettes daily for the last 40 years and drinks one glass of wine occasionally. Other current medications include amlodipine and hydrochlorothiazide. She appears pale. Her height is 163 cm (5 ft 4 in), weight is 75 kg (165 lbs), and BMI is 28

kg/m2. Her temperature is 37.2°C (99.0°F), pulse is 78/min, and blood pressure is 135/80 mm Hg. Cardiovascular examination shows no abnormalities. Abdominal examination shows mild tenderness to palpation in the epigastric region. Bowel sounds are normal. The remainder of the examination shows no abnormalities. Laboratory studies show:

Hemoglobin 10.2 g/dL
Mean corpuscular volume 78 µm
Mean corpuscular hemoglobin 23 pg/cell
Leukocyte count 9500/mm3
Platelet count 330,000/mm3
Serum
Na+ 137 mEq/L
K+ 3.8 mEq/L
Cl- 100 mEq/L
HCO3- 25 mEq/L
Creatinine 1.2 mg/dL
Lactate dehydrogenase 260 U/L
Alanine aminotransferase 18 U/L
Aspartate aminotransferase 15 U/L
Lipase 40 U/L (N < 280)
Troponin I 0.029 ng/mL

An ECG shows normal sinus rhythm without ST-T changes. Which of the following is the most appropriate next step in management?

Tip: Increasing retrosternal pain, weight loss, and anemia in this patient with long-standing reflux and a 40 pack-year smoking history raise suspicion for esophageal cancer. She has risk factors for both adenocarcinoma (gastroesophageal reflux, smoking) and squamous cell carcinoma (alcohol consumption, smoking) of the esophagus.

24-hour esophageal pH monitoring
4%
Twenty-four-hour esophageal pH monitoring is used to confirm the diagnosis in patients with suspected nonerosive reflux disease. While this patient presents with retrosternal chest pain and a burning sensation with meals, suggesting acid reflux, the next step in management should rule out a potential malignancy.

CT scan of the chest
4%
A CT scan of the chest is useful to visualize the entire thorax, including the lungs and the mediastinum. Although this patient presents with red flag symptoms of esophageal malignancy, a CT is more appropriate during the staging process after a malignancy has been confirmed.

Trial of proton-pump inhibitor
12%
An empiric trial of proton-pump inhibitors may be administered if gastroesophageal reflux disease (GERD) is clinically suspected and there are no indications for further diagnostic testing. Although this patient presents with symptoms of heartburn that may suggest GERD, she also has alarm symptoms (e.g., weight loss, anemia) for esophageal cancer, which must be ruled out first.

Esophageal manometry
2%
Esophageal manometry can be used to diagnose motor disorders of the esophagus, e.g., achalasia or esophageal spasms, which may also present with retrosternal pain and weight loss. Because this patient presents with additional alarm symptoms for esophageal malignancy, another diagnostic test is preferred.

Barium swallow
2%
A barium swallow can be used to identify anatomical defects in the esophagus. It is indicated as the initial step in the evaluation of patients with features suggestive of proximal esophageal obstruction, as well as in patients with complicated esophageal strictures (secondary to surgery/radiation/caustic injuries) or with a suspected tracheoesophageal fistula. However, it is not typically considered the best initial step for the evaluation of dysphagia in patients with symptoms predominantly affecting the lower esophagus (e.g., retrosternal pain, heartburn).

Esophagogastroduodenoscopy
77%
Esophagogastroduodenoscopy is the best initial and confirmatory test for suspected esophageal cancer and can also be used to classify reflux esophagitis as well as to detect a peptic ulcer. It should be conducted in all patients presenting with symptoms of gastroesophageal reflux disease (e.g., retrosternal burning pain, regurgitation) and additional alarm symptoms (e.g., weight loss, anemia, melena, dysphagia). If a biopsy confirms esophageal cancer in this patient, further staging of the disease will include an endoscopic ultrasound to determine the infiltration depth and register regional lymph node disease as well as a chest and abdominal PET-CT. Treatment depends on the exact location of the tumor, histopathologic type (adenocarcinoma or squamous cell carcinoma), and the stage.

21. A 42-year-old man with HIV infection comes to the physician because of several episodes of rectal bleeding over the past 2 weeks. He has had pain around the anal area for the past month. Six months ago, he was diagnosed with esophageal candidiasis and was treated with oral fluconazole. He has had 9 male sexual partners over his lifetime and uses condoms inconsistently. The patient's current medications include dolutegravir, tenofovir, and emtricitabine. He is 179 cm (5 ft 10 in) and weighs 66 kg (146 lb); BMI is 21 kg/m2. Vital signs are within normal limits. Digital rectal examination and anoscopy show a hard 2-cm mass palpable 0.5 cm above the anal verge that bleeds on contact. There is no inguinal lymphadenopathy. The abdomen is soft and nontender. The CD4+ T-lymphocyte count is 95/mm3. A biopsy confirms the diagnosis. This patient is most likely to benefit from which of the following interventions?

Tip: Anal canal cancer typically presents as an exophytic, hard anal mass that is often tender and bleeds easily. Squamous cell carcinoma (SCC) is the most common histological type of anal canal cancer (approx. 90% of cases) and it typically arises just above the anal verge and below the dentate line, which is located approx. 2 cm away from the anal verge.

Radiochemotherapy
31%
The incidence of anal canal SCC is higher in individuals that are immunodeficient (e.g., due to HIV infection) and in men who have sex with men (MSM), such as this patient. The combination of chemotherapy and radiation is the treatment of choice for patients with

anal canal SCC. Subsequent surgery is only indicated if a residual tumor is confirmed with biopsy after the completion of radiochemotherapy.

Abdominoperineal resection
9%
Abdominoperineal resection (APR) was formerly the treatment of choice in patients with anal canal SCC. However, a less radical treatment option has been established that has been shown to have higher survival rates than APR. APR is indicated in patients with low-lying rectal adenocarcinomas that can not be treated with sphincter-sparing procedures and those with anal canal adenocarcinomas. Anal canal adenocarcinoma, however, is rare and arises above the dentate line.

Topical trichloroacetic acid therapy
10%
Topical cytodestructive treatment with trichloroacetic acid is indicated in patients with anogenital warts (i.e., condylomata acuminata), for which HIV infection and unprotected sexual intercourse are risk factors. However, condylomata acuminata are usually asymptomatic. They are painful only in a small percentage of cases, and rectal bleeding is a rare sequela. Topical trichloroacetic acid therapy is not appropriate for the treatment of anal canal cancer.

Total mesorectal excision
25%
Total mesorectal excision is usually performed in combination with low anterior resection in patients with rectal adenocarcinoma. However, the patient's tumor is just above the anal verge, within the anal canal, rather than the rectum. In addition, rectal adenocarcinoma is unlikely in a young patient without predisposing factors such as inflammatory bowel disease or a family history of colorectal cancer.

Injection sclerotherapy
5%
Injection sclerotherapy is used in the treatment of patients with rectal prolapse. Rectal prolapse may present with an anal mass and possibly with bleeding, but the mass tends to be painless and typically exhibits radial (partial prolapse) or concentric (full-thickness prolapse) mucosal folds. Furthermore, the patient does not have fecal incontinence, which does occur in most patients with rectal prolapse, nor does he have predisposing factors for this condition such as elevated intraabdominal pressure (e.g., due to constipation or chronic cough) or weakness of the pelvic floor muscles (e.g., due to advanced age or previous perineal surgery).

Submucosal hemorrhoidectomy
20%
Submucosal hemorrhoidectomy is indicated for the treatment of grade IV internal hemorrhoids and lower-grade internal hemorrhoids that are resistant to initial treatment. While internal hemorrhoids may present as an anal mass with bright red bleeding, digital rectal examination and anoscopy would reveal a mass arising above the dentate line rather than just above the anal verge.

22. A 61-year-old woman with a history of stage IV pancreatic cancer comes to the emergency department with insomnia due to intractable midepigastric pain. The pain had been constant for months but has worsened over the past few weeks despite her taking hydrocodone 10 mg and ibuprofen 400 mg. She has chronic pain and major depressive disorder. In the past

month, she has been taking her pain medications with increasing frequency, going from twice a day to four times a day. Her other medications include venlafaxine and eszopiclone. She describes her mood as low without suicidal ideation. She appears fatigued and cachectic. Her temperature is 36°C (96.8°F), pulse is 100/min, and blood pressure is 128/65 mm Hg. Physical examination shows a mass in the midepigastric region. Which of the following is the most appropriate next step in management?

Tip: This patient has chronic cancer pain that is not sufficiently controlled by her current analgesic regimen (as evidenced by insomnia and increasing frequency and total dose of pain medication).

Discontinue hydrocodone and ibuprofen, and start IV ketorolac
13%
Discontinuing her current medications, which include an NSAID (ibuprofen), and starting a different NSAID (ketorolac) is not recommended. Her pain control regimen should be escalated according to the WHO analgesic ladder.

Switch from hydrocodone to hydromorphone
48%
This patient's current pain medications (hydrocodone and ibuprofen) are not providing her with enough pain relief. A switch from hydrocodone to a stronger opioid (e.g., hydromorphone) is the appropriate next step according to the WHO analgesic ladder. When converting between opioids (opioid rotation), patients will likely have less tolerance to the new opioid than to their previous opioid (i.e., incomplete cross-tolerance). Therefore, the new opioid should be given at a 25–50% lower dose, then adjusted according to the patient's pain score. Additionally, this patient should continue taking ibuprofen, as nonopioid analgesics should be used at each step of the ladder for effective and balanced pain relief.

Administer regional block of the celiac plexus using lidocaine
18%
Although nerve blocks using local anesthetics (e.g., lidocaine) may relieve this patient's pain, there are other, less invasive, pharmacological regimens that should be tried first.

Switch from eszopiclone to zolpidem
3%
Switching hypnotics (e.g., from eszopiclone to zolpidem) is not recommended, as this patient's insomnia is most likely due to her uncontrolled pain.

Allow the patient to take hydrocodone and ibuprofen up to every four hours
18%
Increasing the frequency of this patient's current pain control regimen (hydrocodone and ibuprofen) would not be effective. Her current regimen should be escalated according to the WHO analgesic ladder.

23. A 65-year-old man with hypertension and type 2 diabetes mellitus is brought to the emergency department 20 minutes after the onset of severe anterior chest pain and shortness of breath. He has smoked one pack of cigarettes daily for 30 years. He appears distressed. His pulse is 116/min, respirations are 22/min, and blood pressure is 156/88 mm Hg. Pulse oximetry on room air shows an oxygen saturation of 98%. A grade 3/6, high-

pitched, blowing, diastolic murmur is heard over the right upper sternal border. Which of the following is the most likely cause of this patient's symptoms?

Tip: Dyspnea with a high-pitched, blowing, diastolic murmur at the right upper sternal border suggests aortic regurgitation.

Tear in the tunica intima
67%
An aortic dissection is typically caused by a tear in the tunica intima and subsequent longitudinal extension of the dissecting hematoma. Hypertension, which increases the risk of endothelial injury, is the most common predisposing factor for aortic dissection. Most aortic dissections begin in the ascending portion of the thoracic aorta because this is the region of maximum hydraulic stress. Patients present with sudden and severe pain in the chest or interscapular region. The pain can migrate as the dissection progresses. Proximal extension of the dissection into the aortic valve ring can cause acute aortic regurgitation (AR), as seen here. Other features of aortic dissection include syncope, diminished distal pulses, and asymmetrical blood pressure and pulse readings between limbs. Unlike the murmur of AR from aortic valve disease, which is prominent along the left sternal border, the murmur of AR from aortic dissection is prominent along the right sternal border.
Nonmodifiable risk factors for aortic dissection include advanced age, male sex, and certain genetic conditions that weaken the tunica media (e.g., Marfan syndrome, vascular Ehlers-Danlos syndrome, Turner syndrome).

Fibrofatty plaque in the aortic wall
14%
The formation of a fibrofatty plaque in the aortic wall is characteristic of atherosclerosis, which typically involves the abdominal portion of the descending aorta. Atherosclerosis is implicated in the formation of abdominal aortic aneurysms; atheroma ulceration has been reported in some patients with abdominal aortic dissections and descending thoracic aortic dissections. Although both aortic dissection and atherosclerosis share similar risk factors (e.g., smoking, hypertension, advanced age, and male sex), atherosclerosis is not a major risk factor for most aortic dissections, which tend to occur in the ascending aorta.

Obstruction of the pulmonary arteries
5%
Obstruction of the pulmonary arteries is seen in pulmonary embolism, which can manifest with acute-onset dyspnea, chest pain, tachypnea, and tachycardia. However, pulmonary embolism would not explain the AR seen here.

Rupture of a bulla in the lung
1%
Rupture of a bulla in the lung causes pneumothorax, which can manifest with dyspnea, chest pain, tachypnea, and tachycardia. However, pneumothorax would not explain the AR seen here. Instead, chest auscultation would reveal decreased breath sounds caused by pneumothorax.

Perforation of the esophageal wall
0%
Esophageal rupture can manifest with chest pain, tachycardia, tachypnea, and dyspnea (due to mediastinitis and/or pleural effusion). However, esophageal rupture would not cause a murmur. Instead, chest auscultation might reveal a crunching sound over the precordium that is

synchronous with each heartbeat (Hamman sign) due to a pneumomediastinum and/or decreased breath sounds due to a pleural effusion. Furthermore, esophageal rupture usually has a distinct precipitating cause (e.g., retching or forceful vomiting).

Infarction of the ventricular wall
13%
Infarction of the ventricular wall (myocardial infarction) can cause acute-onset chest pain, dyspnea, tachypnea, tachycardia, and a murmur due to mitral regurgitation that is caused by papillary muscle rupture. However, the murmur due to mitral regurgitation is systolic rather than diastolic and heard best at the cardiac apex, not the right upper sternal border. Moreover, papillary muscle rupture typically occurs 2–7 days after infarction, not at the outset.

24. Three days after being admitted to the hospital because of a fall from the roof of a two-story building, a 27-year-old man is being monitored in the intensive care unit. On arrival, the patient was somnolent and not oriented to person, place, or time. A CT scan of the head showed an epidural hemorrhage that was 45 cm3 in size and a midline shift of 7 mm; no skull fracture was shown. Emergency surgery was performed with craniotomy and hematoma evacuation on the day of admission. Perioperatively, a bleeding vessel was identified and ligated. Postoperatively, the patient was transferred to the intensive care unit and placed on a ventilator. His temperature is 37.0°C (98.6°F), pulse is 67/min, and blood pressure is 117/78 mm Hg. The ventilator is set at a FiO2 of 55%, tidal volume of 520 mL, and positive end-expiratory pressure of 5.0 cm H2O. In addition to intravenous administration of fluids, which of the following is the most appropriate next step in managing this patient's nutrition?

Tip: Nutritional support primarily depends on whether a patient is on ventilation (and, if so, for how long) and whether intestinal decompression is required.

Oral feeding
3%
Oral feeding would be inappropriate because the patient is on mechanical ventilation with an endotracheal tube. He cannot ingest food by mouth.

Total parenteral nutrition
23%
Total parenteral nutrition (TPN) via an intravenous line bypasses the gastrointestinal tract. The lack of intestinal stimulation increases the risk of intestinal atrophy, increases bowel wall permeability, and alters the gut flora, making TPN inferior to other feeding methods. TPN is only indicated in patients without a functioning gastrointestinal tract (e.g., short bowel syndrome, severe malabsorption) or when complete bowel rest is indicated (e.g., bowel obstruction).

Keep patient NPO
8%
Nutritional support is indicated in critically ill patients with a low Glasgow coma scale who cannot be fed. Keeping the patient nil per os would only be indicated for the first 48 hours following surgery in case repeat surgery is necessary.

Enteral feeding via nasogastric tube
57%
Critically ill patients with an intact gastrointestinal tract can receive short-term enteral feeding via nasogastric tube (< 2–3 weeks) if there are no contraindications (e.g., bowel obstruction,

intractable vomiting, hemodynamic instability). Enteral feeding is preferred over parenteral nutrition because it stimulates intestinal motility and prevents mucosal atrophy. As long as there is no facial trauma or basilar skull fractures, a nasogastric tube can be used for enteral feeding. When feeding, patients should have their backrest elevated to prevent aspiration and reduce the incidence of nosocomial pneumonia.

Enteral feeding using a percutaneous endoscopic gastrostomy tube
9%
A percutaneous endoscopic gastrostomy (PEG) tube would only be considered for long-term enteral feeding, as temporary routes such as nasogastric or nasoenteric tubes often fail with long-term use because of clogging and inadvertent dislodgement. However, for the short term, a PEG tube would be too invasive in a patient with a potentially reversible condition.

25. A 33-year-old man comes to the physician because of right scrotal swelling for the past 2 weeks. He has had mild lower abdominal discomfort for the past 3 weeks. There is no personal or family history of serious illness. He appears healthy. Vital signs are within normal limits. Examination shows gynecomastia. There is no inguinal lymphadenopathy. There is a firm nontender nodule over the right testicle. When a light is held behind the scrotum, it does not shine through. When the patient is asked to cough, the nodule does not cause a bulge. The abdomen is soft and nontender. The liver is palpated 2 cm below the right costal margin. Digital rectal examination is unremarkable. Serum alpha-fetoprotein, LDH, and hCG levels are markedly elevated. An x-ray of the chest shows no abnormalities. Ultrasound of the testis shows a cystic 3-cm mass with variable echogenicity. A CT of the abdomen shows multiple hypoattenuating lesions on the liver and retroperitoneal lymph nodes. Radical inguinal orchiectomy with retroperitoneal lymph node dissection is performed. Which of the following is the most appropriate next step in management?

Tip: A nonhomogenous, cystic testicular mass with a negative transillumination test and multiple hepatic and lymphatic lesions is highly suggestive of metastatic testicular carcinoma. Extranodal/distant metastases at the time of presentation and increased alpha-fetoprotein (AFP) levels make a nonseminomatous germ cell tumor (NSGCT) the most likely type of tumor in this patient.

Radiation therapy
26%
External beam radiation is used to clear the retroperitoneal lymph nodes off of micro-/macrometastases in early stage (I, IIA, IIB) seminomatous germ cell tumors, which are extremely radiosensitive. However, radiation therapy is generally not used in the treatment of NSGCTs because these tumors are comparatively radioresistant. The only indication for radiation therapy in patients with a NSGCT is brain metastases (e.g., whole brain irradiation).

Cisplatin, etoposide, and bleomycin therapy
44%
Adjuvant chemotherapy with cisplatin, etoposide, and bleomycin (BEP regimen) can be considered in stage I nonseminoma in select patients and is usually indicated in stages II and III. This patient has signs of advanced NSGCT with metastases to his liver and increased tumor markers (stage IIIC). In addition to the radical inguinal orchiectomy, he would likely require 4 cycles of this regimen due to the advanced nature of his cancer. Patients with nonseminomas have a significantly poorer prognosis than patients with seminomas, but still an excellent overall survival rate.

Leucovorin, 5-fluorouracil and oxaliplatin therapy
20%
The combination of leucovorin, 5-fluorouracil, and oxaliplatin (FOLFOX) is used for the treatment of colorectal cancer. It is not used for testicular cancer.

Active surveillance
10%
After an inguinal orchiectomy, active surveillance consisting of regular follow-up exams, serial monitoring of tumor markers, and imaging (abdominal and pelvic CT, chest x-ray) may be indicated in select patients with early-stage (IA, IB) nonseminomatous germ cell tumors (NSGCTs) without elevated tumor markers. However, any NSGCT of stage II and above or any NSGCT with elevated tumor markers requires a specific form of adjuvant therapy after orchiectomy.

Stem cell transplant
0%
A peripheral blood stem cell transplantation is indicated for patients who require high-dose chemotherapy, which has a myeloablative effect. However, high-dose chemotherapy is preferred in testicular cancer over conventional chemotherapy only in patients with an incomplete response or recurrent disease following the first-line of adjuvant therapy. Stem cell transplantation is not required following the conventional first-line adjuvant therapy.